TELKOMNIKA Telecommunication Computing Electronics and Control
Vol. 23, No. 6, December 2025, pp. 1528~1542
ISSN: 1693-6930, DOI: 10.12928/TELKOMNIKA.v23i6.27191

An insight on using deep learning algorithm in diagnosing gastritis

Ragu P. J.[1], Ashok Vajravelu[1], Muhammad Mahadi bin Abdul Jamil[1], Syed Riyaz Ahammed[2]
[1]Faculty of Electrical and Electronic Engineering, Universiti Tun Hussein Onn Malaysia (UTHM), Johor, Malaysia
[2]Department of Electronics and Communication Engineering, NITTE University, Mangalore, India

Article Info

Article history:

Received May 5, 2025
Revised Sep 23, 2025
Accepted Oct 19, 2025

Keywords:

Deep learning
Diagnosis system
Gastritis detection
GoogleNet
ResNet
TResNet
VGGNet

ABSTRACT

Chronic autoimmune gastritis (CAG) is a condition in which the stomach membrane is significantly impacted by inflammation. Despite the availability of numerous modern medical techniques, the detection of this condition continues to be a difficult challenge. White light endoscopy (WLE) has been employed to diagnose gastritis, but it has been subject to certain constraints. This technique is most effective when executed by an endoscopist who possesses a high level of expertise. In the present day, WLE is frequently accompanied by artificial intelligence (AI) due to its superior ability to detect defects that lead to damage. Recently, there has been a substantial increase in the efficacy of AI in conjunction with the expertise of endoscopists in the detection of CAG. The 25,216 intriguing case studies were examined in the eight selected studies. The collection comprised 84,678 frames and 10,937 images. The AI was 94% sensitive (95% CI: 0.88-0.97, I2 = 96.2%) and 96% specific (95% CI: 0.88-0.98, I2 = 98.04%). The receiver operating characteristic curve had an area of 0.98 (95% confidence interval: 0.96–0.99). A camera is highly effective when combined with AI to assist in the identification of CAG and is advantageous for clinical review.

This is an open access article under the CC BY-SA license.

Corresponding Author:

Ashok Vajravelu
Faculty of Electrical and Electronic Engineering, Universiti Tun Hussein Onn Malaysia (UTHM)
86400 Parit Raja, Batu Pahat, Johor, Malaysia
Email: vashok.research@gmail.com

1. INTRODUCTION

Gastroenteritis is a condition characterised by inflammation that results in the enlargement of the stomach lining and the subsequent onset of discomfort. The majority of individuals who experience minor gastrointestinal inflammation do not exhibit any symptoms, which is why it may not be classified as a clinical disease. Rather, it is referred to as a histological disease that affects tissues. It may be the result of the illness, anxiety, general malaise, failure to adhere to medication instructions, inflammatory disease, gastric reflux, or excessive alcohol consumption. A substantial number of individuals worldwide are affected by gastritis. Helicobacter pylori (HP) bacteria are the primary cause of an increased number of intestinal ailments in approximately 50% of the global population. The updated Sydney system can be used to precisely describe and evaluate gastroenteritis [1]. Different forms of gastritis can be classified based on the location of their origin, the appearance of the infection, and the cause of the various forms of gas in the stomach. It may be a one-time infection, long-term infection, or short-term infection. A sample is employed to quantify the quantity and composition of defecation during an upper gastrointestinal (UGI) endoscopy. The operative link on gastritis assessment (OLGA) illustrates the numerous phases of gastritis. By observing the diverse

symptoms, individuals who have been diagnosed with gastritis may appear to be more confident in their diagnosis.

Furthermore, dyspeptic syndrome, anaemia syndrome, or haemorrhage in the UGI tract may be experienced by individuals with gastritis. The most prevalent diagnosis detected during an UGI tract endoscopy is swollen gastric tissue. It is essential because it offers a histology report and a test to identify gastritis. In the past decade, a substantial amount of research has been conducted to investigate the potential of artificial intelligence (AI) to aid physicians in making more informed decisions in the field of medicine. Deep learning is the most common form of machine learning for analysing objects by omitting non-evident components from the images, and minor matters are debated at a rapid tempo. Several individuals have expressed interest in AI because of its potential to transform the methods of disease detection and treatment, particularly in the disciplines of gastroenterology and liver disease, which frequently employ visual aides [2]. AI is now capable of identifying minute modifications in the mucosa, such as polyps or early signs of cancer. Physicians were obligated to review a plethora of records and photographs captured with a specific camera in order to ascertain the most suitable course of treatment. Furthermore, AI is capable of observing images in progress by gazing through a lens.

The physician will be able to make a more precise decision in a brief amount of time, and the patient will receive the necessary medications for recovery. AI can help detect gastric cancer (GC) at an early stage, which can facilitate the recovery of the illness and reduce its rapid dissemination. Persistent gastritis is one of the primary symptoms. Chronic gastritis that deteriorates over time may lead to growths that have the potential to develop into cancer. Diverse terms, including dysplasia, metaplasia, and atrophic gastritis (AG), may be employed to identify these chronic diseases. The term "gastric adenocarcinoma" is typically employed to denote the specific form of stomach cancer that these lesions will develop over time. The research is meticulously designed to exhibit the functionality of AI and its capacity to identify individuals who frequently vomit without understanding the repercussions [3]. Additionally, numerous studies have been conducted to diagnose gastritis using AI tools. The advantages and disadvantages of these methodologies, which are employed to identify GC, were thoroughly examined. AI has the potential to revolutionise the process of detecting accurate possibilities of maladies and assisting with a variety of analytical techniques. The comprehensive investigation conducted with AI has evolved as a result of ongoing research in a variety of applications.

Individuals who suffer from stomach ulcers are at an increased risk of developing mucosa-associated lymphoid tissue cancer, stomach adenocarcinoma, or immune thrombocytopenic purpura. These microorganisms are typically observed in more than 50% of the global population. Starting with a general ailment, it progresses to intestine metaplasia (IM), chronic AG, and, in the end, stomach cancer. According to the International Agency for Research on Cancer (IARC), individuals who are initially afflicted with HP do not suffer from any symptoms; however, they frequently develop gastritis. In general, a significant number of individuals are of the opinion that the most effective method of preventing GC is to eradicate this infection. In the interim, the severity of diseases is underscored by the examination of the musculature in the stomach through endoscopy. This test can ascertain whether HP is capable of causing gastritis. Certain patients may undergo this method to identify those who are most susceptible to developing GC. The various aspects of gastritis caused by HP have been the subject of numerous studies and publications. Oedema may be present in the posterior region of the pharynx, and the lips may contract or expand.

In certain individuals, symptoms may be able to identify the region of the intestines where HP do not reside due to the proliferation of fundic glands and venules. Blue laser imaging (BLI) endoscopy may be implemented to investigate the gastro intestinal tract's interior through white-light endoscopy (WLE). These two methods provide a comprehensive understanding of the early symptoms of GC. To be more specific, it assists in the identification of lesions, particularly in regions that are challenging to detect. Some individuals have concluded that the lining of the stomach and the wall of the colon are interconnected as a result of these facts. The infected regions may not be accessible to individuals who are infected with HP. HP infection can be identified by thoroughly analysing the tissue by specific endoscopists. Nevertheless, the clinicians may be required to take a substantial amount of time to complete this task accurately. Image-enhanced endoscopy (IEE), is a novel technique that includes narrow-band imaging (NBI), broad-band imaging (BBI), and linked colour imaging (LCI). The identification of gastric malignancies by physicians has been facilitated by this method. These sophisticated methods can be employed to identify the location of the lesions' origin and to characterise them, particularly in the gastrointestinal tract. The timing of HP detection in IEE is not discernible. At present, endoscopy is not a reliable method for determining whether an individual has an HP infection.

In order to determine the precise nature of the infection, the physician must also conduct an endoscopic biopsy or another form of internal examination [4]. AI is essential in nearly all industries. It is progressively increasing in use in the healthcare sector, aiding physicians in the process of identifying diseases and determining personalised treatments. Additionally, it mitigates numerous technical deficiencies

that are manually generated. The images, which were obtained through an endoscopy, offer a wealth of information about the specific disease. In this case, they can ascertain whether these growths in the digestive system are harmful. It may be advantageous to possess AI that is capable of analysing images captured by a camera. Physicians can develop methods for testing HP conditions and acquire knowledge about them. Negative bacteria are comprised by HP, a round bacterium. It is present in more than 50% of the global population. It is designated as a category I malignancy. The clinical evaluation would be straightforward to cure the diseases if the screening is conducted in the early phases, according to the World Health Organization (WHO). Approximately 23% to 35% of individuals who have HP experience gastrointestinal illness. One of the infections in the stomach that results in facial oedema and discolouration is immune thrombocytopenic purpura [5]. It will be challenging for all individuals who have contracted HP. Eliminating HP at an earlier stage is the most effective approach for individuals who have it.

A variety of methods have been devised to ascertain whether an individual has contracted HP infection. However, each method has its own set of benefits and drawbacks. Regardless of the utilisation of an endoscopy camera, these assessments are either direct or indirect. The urea breath test (UBT), stool antigen test (SAT), and HP immunoglobulin G (IgG) in the blood are among the assays that will not result in any adverse effects. The SAT or the UBT can be employed to ascertain whether an individual has an HP infection. UBT is less effective for individuals who have undergone stomach surgery or who take medications that alter the pH value of the stomach walls. This method is uncomplicated, inexpensive, and unable to differentiate between ancient and new diseases. An alternative and more invasive method of determining whether an individual has an HP infection is an endoscopy. The following are some of the indicators of gastritis caused by specific strains of HP:

- Atrophy is a condition in which the size of an organ or tissue decreases.
- Diffuse erythema is a condition characterised by patches of redness and inflammation in the digestive tract.
- Mucosal oedema is characterised by the accumulation of fluid in the nose, mouth, pharynx, and phyranx.
- Distended pleats - a distended lining of the intestines.
- Nodularity is the development of a mass beneath the airways.

The accumulating venules and stomach foveolar lesions are configured differently in individuals who do not have HP in their intestines.

A substantial quantity of time and specialised skills are required to make a decision based on investigation. Each individual undergoes a unique experience. If the endoscopist is inadequately trained, this examination may generate false positives and negatives. A novel perspective is required to investigate the interior of the stomach. This is the “gold standard” method for identifying tumours and determining the most effective treatment. The proliferation of HP is evaluated in all gastrointestinal samples that are collected in the histology laboratories. It is imperative to have a lens that is capable of observing at least one of the bugs in order to identify its species. In numerous instances, the outcomes were disregarded. Despite the fact that Hematoxylin and Eosin (H&E) spotting is highly effective in identifying HP in the presence of a high volume of bacteria, this remains accurate. There are numerous techniques that can be employed; however, they are more costly and necessitate a longer duration to complete the bacterial identification process.

The examination of medical images has reached a milestone that has never been achieved before, thanks to AI and deep learning. In the past, it was necessary for individuals to examine a tissue sample through a microscope after extracting it from a body part in order to detect HP. Nevertheless, these methods are not always effective and are only effective in specific locations. AI can now be implemented in innovative ways to facilitate the detection of HP through the use of these new camera images. AI has the capacity to complete some advantageous duties; however, their efficacy is contingent upon specific factors, such as the quality of the images, the quantity of data they contain, and the way in which they are configured [6]. The primary goal of the research is to assess the capacity of AI to distinguish between images of an HP infection and other health issues.

2. DIAGNOSIS SYSTEM FOR GASTRITIS DETECTION

This section has extensively examined the potential of deep learning to identify images of medical objects. It also clarifies the typical occurrence of gastrointestinal issues.

2.1. Overview and status of gastrointestinal diseases

The initiative aims to enhance the efficiency of identifying ailments by utilising AI. The quality of healthcare for individuals worldwide has the potential to be improved by this investigation. The initial three sections are concerned with the operation of objects, while the subsequent three sections are concerned with

anatomy. Two distinct procedures can be employed to remove polyps from the blood vessels. An image of the body regions responsible for food assimilation is included in the Kvasir collection. Each year, this malignancy leads to the fatalities of 1.8 million individuals. Annually, it is contracted by more than 2.8 million individuals. This area of the body is susceptible to a wide range of ailments. This procedure is the most effective for observing the interior of the stomach. The oesophagus, the stomach, and the initial portion of the small intestine can be observed by the physician during a gastroscopy. These are all elements of the stomach's anterior region. In contrast, a colonoscopy is a procedure that exclusively evaluates the colon [7]. High-quality images that were captured in real time are employed to conduct all of these evaluations.

It is imperative to promptly diagnose the disease and eliminate any lesions through endoscopic surgery before obtaining the appropriate treatment. The probability of developing colon cancer is high. Colon cancer detection necessitates a robust set of abilities. If the doctor is unable to precisely interpret the images, they may be unable to definitively determine whether the individual has colon cancer. In this case, the physicians should promptly evaluate the information collected regarding the identification and investigation of gastrointestinal malignancies by identifying data that is not immediately apparent. Hospitals and institutions benefit from this approach. The PRISMA flow diagram, as depicted in Figure 1, outlines the concept of systematic literature review and the process of research selection for the investigation of optimisation methods in deep learning for the diagnosis of gastritis. The abundance of records at each stage, from the initial identification to the final study inclusion, is depicted in Figure 1.

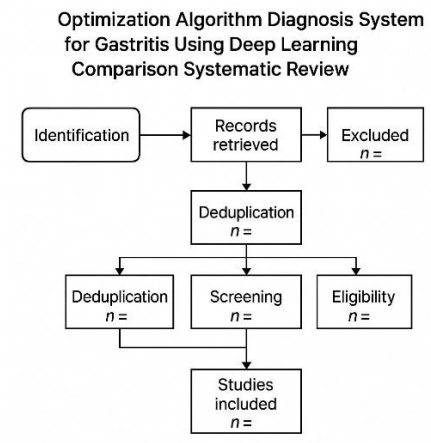

Figure 1. PRISMA flow diagram

2.2. Artificial intelligence-powered gastritis detection system

Convolutional neural networks (CNN) are predominantly an algorithm that can be employed to recognise and analyse any type of visual data. CNN is currently involved in nearly every industry. For example, in the healthcare industry, it is essential to identify early signs of illness in order to ascertain the underlying cause. CNN is considerably more proficient in comprehending images than is possible through manual processes. Three layers are present in CNN: convolutional, shared, and completely linked. CNN is more proficient in the manipulation of images than recurrent neural networks (RNN) and other networks. Furthermore, a methodology referred to as "learning transfer" is implemented. Transfer learning is a form of machine learning in which a model is trained on a task and subsequently used to perform a related task. CNN is founded on the assumption that images captured by real-time data can convey information. Recently, CNNs have become increasingly prevalent in the detection of gastritis due to their ability to provide a more rapid and precise diagnosis than the manual analysis performed by endoscopists. The trained dataset of endoscopic images that is associated with gastritis is contained in CNN. The images possess CNN characteristics; they are already present in the material they acquire [8].

2.3. Overview of deep learning architectures

Inception V1 is the name of the GoogleNet form of CNNs. It was created by professionals who are employed by Google. Eighteen levels are present when the levels that are connected are accounted for. The 2014 imagenet large scale visual recognition competition (ILSVRC) was a competition to ascertain which building could expedite the process of image classification. GoogleNet emerged as the victor. This is not the sole objective of GoogleNet. Additionally, it can be employed to observe objects on a computer and other

devices. The GoogleNet's construction is depicted in Figure 2. Approximately 5,000 images of gastritis diseases that affect the lower digestive system are included in these categories. It consists of 27 levels. Certain measures are irrevocable. There are numerous levels. At the outset, the image is 224 pixels by 224 pixels and is set to an red, green, blue (RGB) colour scheme. The initial stage is distinguished by the presence of two 7×7 displays, as opposed to four. A substantial number of the displays on it exceed the image configuration mentioned earlier. The succeeding layer is a convolutional layer that includes a 3×3 filter. The final layer is an optimal pool layer that employs 3×3 displays. This portion of the image obscures the initial image. Table 1 contains the distribution of deep learning architectures that are employed to diagnose gastritis. The quantity of research conducted in each category and the specific designs within it were also illustrated in Table 1. The architectures are categorised into CNN-based, RNN-based, Transformer-based, and Hybrid models in the Table 1.

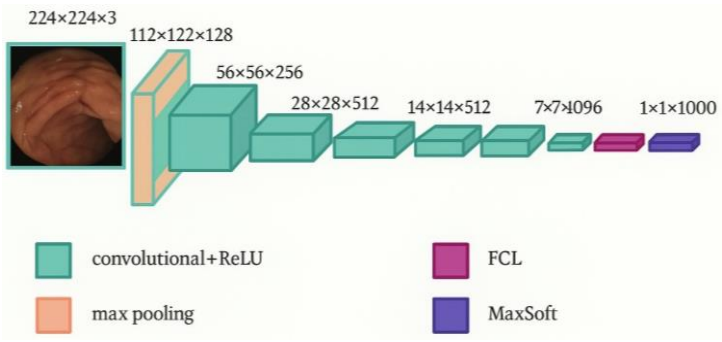

Figure 2. GoogleNet structure for diagnosing gastrointestinal disease

Table 1. Provides an overview of the deep learning architectures employed across the included studies

Architecture types	The number of research	Certain architectures
CNN-based	24	There are nine residual network (ResNet) models, five visual geometry group (VGG) models, four Inception models, three DenseNet models, and three custom CNN models
RNN-based	5	Long short-term memory (LSTM) (3) and gated recurrent unit (GRU) (2)
Based on transformers	7	Eye transformer 4, detection transformer (DETR) 2, and swin transformer 1
New hybrid models	6	These are CNN-LSTM (3), CNN-transformer (2), and CNN-attention (1)

The purpose of transmitting information to a specific location is to serve as a launching point. A three-by-three screen layer is the most effective pool layer. Ultimately, an idea module is constructed using a four-layer block. A maximal pool layer with three-by-three screens has been incorporated following this process. The succeeding module is an introductory module that includes two sets of blocks. The final phase involves the installation of an optimal pool layer with three-by-three screens. The median of the preponderance of pools is 7 pixels in breadth and 7 pixels in height. The "Stroke" number denotes the degree to which the filter modifies the image. Preventing overfitting is one of the objectives of the Dropout method. It was anticipated that a 40% attrition rate would occur during the research. Whenever a new set of numbers is employed, forty percent of the neurones are rendered nonfunctional. It eliminated 40,966 features and reinstated 9,216 features. The softmax layer is divided into five categories when the architecture functions properly [9]. A wide range of polyps, such as those that have grown, been drawn, or have a normal cecum, are included in this category.

2.4. Smart diagnostic approach for gastritis

CNN ResNet-50 is an architecture that comprises 177 levels. ResNet-50 is employed to perform a variety of computer vision duties. The ResNet-50 is assembled in the manner depicted in Figure 3. It was employed to organise 5,000 images into five categories. ResNet-50 is represented by sixteen segments. Each segment consists of 177 steps. Distinct filters are implemented at each of these 49 convolutional layers. RGB images with dimensions of 224 pixels by 224 pixels are transmitted to the input layer. It produces deep feature vector representations of the most critical components of each image you submit. Access to the upper and lower figures is facilitated by the "pooling" element. The feature vector map is not as expansive as it

could be as a result of these two levels. Consequently, the network's most effective method of acquiring knowledge is aggregate uniformity. Nevertheless, the rectified linear unit (ReLU) function, which is implemented subsequent to the convolutional layers, exhibits exceptional performance. Everything that is not zero is converted to zero. It is capable of transmitting and receiving 4,966 features when it is fully connected. It is capable of transmitting and receiving 1,000 features at the second linked layer. Five distinct groups are produced by the softmax layer during this operation. The organisations are as follows: having polyps, ulcerative colitis, a healthy cecum, a healthy pylorus, and polyps simultaneously is feasible.

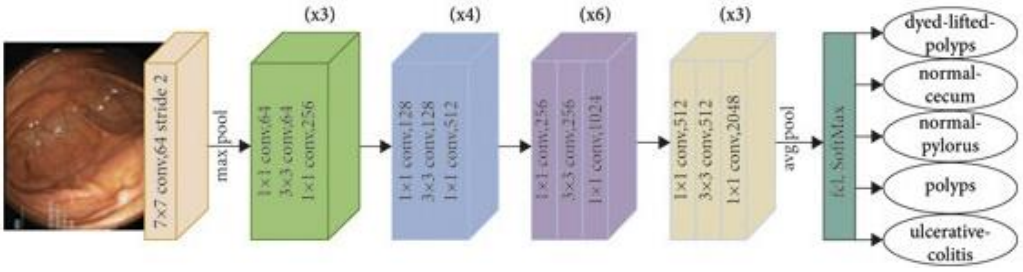

Figure 3. Architecture of a ResNet-50 for gastrointestinal disease diagnosis

CNN is featured on AlexNet. The 2012 ImageNet classification challenge was won by AlexNet. It was inaccurate 15.3% of the time. These models were employed to generate five sets of 5,000 injections, one for each form of gastrointestinal disease. Figure 4 illustrates the AlexNet's construction. AlexNet's methodology comprises twenty-five phases. A unique filter is included in each of the five convolutional layers. Upon its arrival, it is supplied with 227×227 RGB images. The convolutional layer is responsible for the processing of images and the extraction of deep data. A maximum of three stages must be taken into account. The object that is diminutive in the image is taken into account. Two procedures must be taken into account to guarantee that all networks are consistent. Prior to attaining the most rapid reading tempo, the vectors' weights must be adjusted. There are seven layers, which are preceded by the convolutional layers from [10]. Each number that ReLU furnishes is precise. One positive number is distributed for each negative number. When they collaborate, the three strata execute their responsibilities in the appropriate order. In addition to the 9216 characteristics that are presently available, 4096 additional characteristics are acquired when the initial linked stratum descends. 49 characteristics are present in the second stratum of the first layer. It is endowed with 1000 neurones, which are an alternative term for features. The third stratum is the only one that is wholly united. Each polyp is distinctive. The five kinds are normal cecum, pylorus, ulcerative colitis, and dyed-lifted polyps.

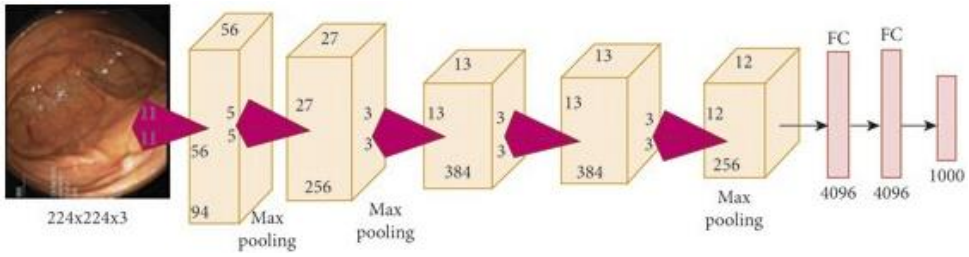

Figure 4. Architecture of an AlexNet for gastrointestinal disease diagnosis

2.5. Background on gastritis

In 2020, the IARC anticipates that more than one million individuals will develop GC and that 700,000 individuals will succumb to the disease at random. An approximated 500,000 individuals per year succumb to this malignancy. According to Correa and Houghton [11], there are numerous methods by which GC that originates in the intestines can disseminate. A feeling of well-being is experienced by an individual who has a sound digestion. Chronic autoimmune gastritis (CAG) and chronic non-atrophic gastritis (CNAG) are the two types of gastritis. The term dysplasia is derived from the Latin words for "wrong growth" and the subsequent one is GC in the stomach. This illness captivates a significant number of individuals. According

to a study conducted in the Netherlands, stomach cancer is developed by 0.1% of individuals with AG and 0.2% of those with intestinal metaplasia (IM) each year. According to a ten-year study conducted in Japan, individuals with mild to severe atrophy possessed 3.4% to 16% more GCs than those without atrophy. The percentage of individuals with IM varied from 11% to 16%. Table 2 compares the diagnostic capabilities of numerous deep learning architectures for gastritis. This comparison encompasses the aggregated specificity, area under the curve (AUC), accuracy, and sensitivity, as well as the number of papers reporting each design. Enclosed in parenthesis are the 95% confidence intervals for the values mentioned.

Table 2. Presents the performance metrics of different deep learning architectures for gastritis diagnosis using endoscopic images

Building plans	How accurate (%)	How sensitive (%)	Level of detail (%)	AUC	The number of research
ResNet-50	81.2 (77.6-83.5)	80.0 (76.1-82.7)	82.3 (78.4-84.6)	0.832	7
VGG-16	78.4 (75.0-80.7)	77.2 (74.3-80.1)	80.5 (76.8-82.0)	0.801	4
Inception-v3	80.0 (76.3-81.7)	78.1 (74.6-81.2)	80.6 (77.2-83.1)	0.514	3
DenseNet-121	80.6 (77.1-82.8)	80.2 (76.0-81.7)	81.4 (78.3-83.6)	0.8276	2
ViT-B/16	77.8 (74.2-80.6)	76.3 (73.1-80.4)	78.4 (75.7-81.0)	0.803	3
CNN-LSTM	90.8 (87.6-93.4)	78.6 (75.2-81.4)	80.8 (77.4-83.2)	0.816	2

This was finalised upon the permanent eradication of HP. It has been generally observed that individuals residing in East Asia who possess the CAG gene have a higher likelihood of receiving GC. This represents a unique concept. According to a study conducted in Korea, 18.4% of individuals with an average GC also had CAG. GC was detected on the bodies of more than 52.5% of individuals. If one is cognisant of CAG from the Inception, it is possible to prevent GC. This is accurate because GC has the potential to cause malignancy. Gastroscopy entails the excision of a portion of flexible gastrointestinal tissue and its examination through a small lens. This technique is considered the “gold standard” for determining CAG. A white light-emitting camera is the primary element of therapeutic endoscopy. These facilitate the visualisation of the layers of gastrointestinal mucous. The physician will determine whether or not a patient requires the test based on their abilities. WLE is only capable of detecting cardiac disease CAG in 42% of cases. In 65% of cases, standard WLE was capable of distinguishing between two objects in the gastric sinus. It has the potential to distinguish between the abdominal body and something else in 76.4% of cases. There is a growing trend among individuals to identify CAG on a computer or a virtual colour camera.

The physicians participate in this activity because it fosters their professional growth. When CAG is suspected as the underlying cause, the physician decides to implement WLE. In order to make an informed decision regarding the course of treatment, the endoscopist must possess the requisite skills. It can be difficult to administer the treatment effectively when endoscopists are fatigued or inexperienced. The treatment may be costly and time-consuming. Furthermore, they may result in an elevated incidence of gastrointestinal haemorrhage. The treatment should be both equitable and convenient for the purpose of locating CAG. AI techniques are employed by endoscopists to analyse images. AI primarily employed computer vision to identify lesions, organise them according to their semantic content, and classify images into distinct categories.

3. GASTRIC DISEASE AND DEEP LEARNING

VGGNet, ResNet, TResNet, and SE-ResNet are applied by physicians to devise medical images. It is possible to determine the type of image by using algorithms like, R-CNN, YOLO, and single shot multibox detector (SSD) which are among the optical character recognition (OCR) tools that can be employed to identify and designate specific elements in an image. Squares can also be employed to enclose those items. It is also beneficial to draw boundaries around those items. Semantic segmentation is the term that refers to this approach [12]. Algorithms include DeeplabV3, UNet++, and U-Net.

Figure 5 illustrates the three methods, their similarities and differences. To further clarify the distinctions among these approaches, Figure 5(a) represents image classification, where the model assigns a single diagnostic label to the entire endoscopic image. Figure 5(b) shows object detection, which identifies relevant abnormalities and marks their locations with bounding boxes. Meanwhile, Figure 5(c) depicts semantic segmentation, a more detailed technique that assigns pixel-level labels to precisely outline the boundaries of gastritis-related lesions. These collectively demonstrate how different deep learning frameworks operate when analysing gastrointestinal endoscopic images. If AI is capable of accurately identifying CAG on the videocast, then it serves as a greater aid in treatment. CAG is necessary to examine the results of a variety of experiments.

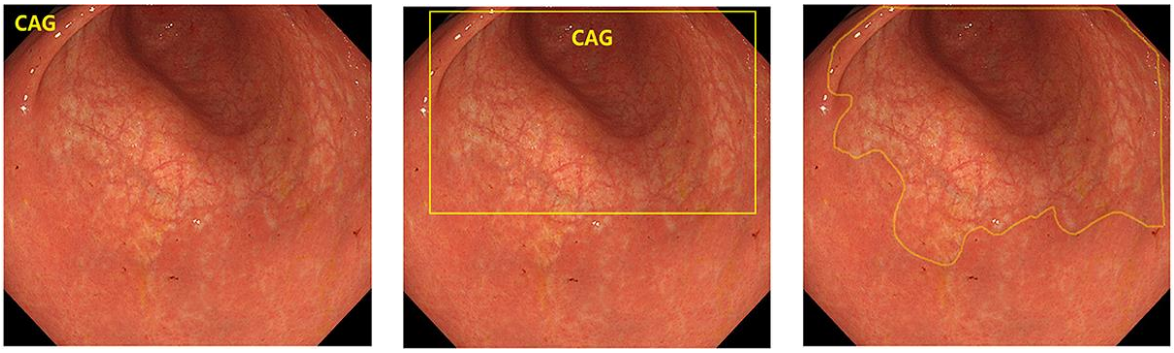

(a) (b) (c)

Figure 5. Difference among the three types of deep learning algorithms: (a) image classification, (b) object detection and (c) semantic segmentation

The purpose of the investigation is to ascertain the degree to which AI can accurately identify CAG. AI may be compared to endoscopists, and the numerous obstacles that impede its ability to diagnose may also be observed. Gut cancer, is a highly probable diagnosis for all individuals. GC is developing at an accelerated rate in a substantial number of individuals worldwide. Given this, it is strongly advised that more efficient methods be developed for the identification of lesions in individuals. One in every five individuals is diagnosed with this form of cancer, which has the potential to increase metastasis. At present, it is more lethal and may result in the mortality of cancer patients. Nevertheless, the prevalence of this malignancy is declining. They predict that it may affect 62% of the global population by 2040. By 2040, the IARC anticipates that 1.3 million individuals will succumb to cancer and 1.8 million will develop it. The situation may deteriorate if the appropriate technique for detecting the illness is not implemented. In five years, only 66.5% of individuals with stage II and III cancer will survive. Nevertheless, 80% of individuals who have been diagnosed with stage I cancer will survive. Life expectancy is subject to change over time. This illustrates the importance of early detection of GC.

The intestine may suggest the presence of neoplasias, despite its apparent inconsequentiality. Five to ten percent of individuals who were diagnosed with GC three years later underwent an upper endoscopy designed to identify the absence of cancer. In other words, the appropriate approach was not employed to detect gastric malignancies in their initial stages. Endoscopists who are not proficient in their discipline identified certain malignancies. An additional 14% of malignancy has been detected by certain endoscopists; however, this discovery was made after the procedure had already been completed [13]. AI has made some progress in endoscopy thus far, which is a positive development. AI tools that can rapidly identify computer-aided detection (CADe) and locate computer-aided diagnosis (CADx) new growths in the stomach can be of assistance to clinicians. To achieve this, they analyse the gut cells for minute alterations that may suggest the presence of malignancy. Deep learning, an essential element of AI, is facilitated by neural networks, which are similar in nature. These networks contain components that have the capacity to enhance or modify data. Modifications to the network are implemented over time to reduce the probability of an incident. Deep learning is a collection of interconnected processes. It has now recognised distinct tendencies that were previously undetectable. It is advantageous for various purposes, including comprehending and visualising words and images. The internet [14], enhanced processors, and the vast amount of data it contains have all contributed to the substantial advancements in this field.

In the present day, AI tools are applicable in nearly all sectors, including the auto industry, customer service, banking, and hospitals. Now, numerous individuals are capable of developing AI models by employing tools like TensorFlow and PyTorch. As a result, the comprehension and application of AI have been simplified. It is being incorporated into an increasing number of products and services, and numerous business sectors are utilising these tools to an even greater extent. CNNs, are a deep learning model that is employed in a variety of fields. It acquires knowledge by observing a multitude of films and images that include annotations. In order to facilitate their organisation and classification, these videos and images are tagged. Based on the labelled images, the AI model is capable of distinguishing between healthy and malignant epidermis. This is the reason for the disintegration. At the outset, it is imperative to acquire and modify the internal images. Subsequently, cells that are anticipated to be hazardous will be identified and marked. The accuracy, sensitivity, quantity of detail, AUC, and number of research papers that employed each model are summarised in Table 3, which contrasts the performance of multiple deep learning architectures employed for gastritis diagnosis. Confidence intervals are denoted by values in parenthesis.

Table 3. Illustrates the performance metrics of different deep learning architectures for gastritis diagnosis using histopathological images

Building plans	How accurate (%)	How sensitive (%)	Level of detail (%)	AUC	The number of research
ResNet-50	83.5 (81.7-85.3)	82.4 (80.1-84.6)	84.0 (81.3-86.2)	0.851	4
VGG-16	80.6 (77.8-82.7)	90.8 (66.5-82.3)	81.4 (78.6-83.7)	0.932	3
DenseNet-121	82.7 (80.0-84.8)	81.6 (78.4-83.8)	83.2 (80.7-87.1)	0.953	3
Swin transformer	81.3 (78.6-83.5)	80.2 (77.0-82.7)	82.0 (80.4-84.3)	0.942	1
Custom CNN	78.4 (75.1-81.0)	77.3 (73.8-80.2)	80.1 (76.5-81.8)	0.911	2

Currently, it is uncomplicated to identify and resolve issues in any sector. By examining new images, individuals who have acquired knowledge on AI can readily identify gastric neoplasia(s) (CADe) or detect them (CADx). The most effective methods for the detection of gastrointestinal cancer and other tumours in the UGI tract are a computed tomography (CT) scan and a colonoscopy. AI can occasionally forecast the profundity of GC, which is advantageous for the determination of treatment at an earlier stage. This AI is frequently capable of identifying the issue with the same precision as skilled endoscopists. Furthermore, this method may be implemented to distinguish between gastric intestinal metaplasia (GIM) and healthy gastrointestinal tissue. The procedure of gastrointestinal endoscopy can be transformed by AI. Nevertheless, the integration of CADe and CADx instruments is not always evident. The resolution of numerous issues is required by AI's functionality. AI and individuals do not consistently accomplish the outcomes they anticipate. Deep learning is capable of a wide range of tasks, including the identification of brain cancer through speech and image recognition. The research paper examines the benefits and drawbacks of employing a microscope in a CNN-style approach to identify the development of gastritis in the intestines. In 2020, a report was released by an IARC that predicted that 1,109,103 individuals would develop GC, and 768,793 would die from the disease. This specific region of the body is responsible for 5.6% of new cases and 7.7% of deaths, ranking fourth in terms of cases and fifth in terms of fatalities.

Gastric adenocarcinoma is the term used to describe this form of stomach cancer. Before GC develops, growth can endure a variety of stages. GC is 1.9% more likely to develop in individuals with CAG within the next five years. CAG is present in over 50% of the population in China and Japan, according to a restricted number of assays. A gastroscopy with samples is the "gold standard" method for detecting CAG. It is remarkable to determine the extent to which the endoscopist is capable of conducting biopsies. CAG can be detected by a WLE; however, it is not particularly effective in this manner. When a camera is employed, AG is most frequently identified in the antrum (61.5%) and the stomach body (46.7%) [15]. Eradicating ailments that were overlooked by the physician as a result of human error is a difficult task. The physician is obligated to execute this task manually, as opposed to employing a machine. Endoscopists are not obligated to conduct any additional tests if they are able to locate CAG with ease and clarity. The rate of stomach cancer development will either be reduced or eliminated entirely if this is combined with deep learning and other forms of AI. Over the past few years, they have been extensively utilised in a variety of medical imaging applications. Additionally, individuals who have experienced gastritis may experience nausea as a result of AI-based methodologies.

In 98% of cases, the deep learning method with a computer is effective in detecting early GC. It was precise 98.7% of the time. A small ensemble was employed to capture the images. A CNN was employed in a series of experiments to ascertain its capacity to identify HP cases. With a performance of 87.7%, it was intelligent at 88.9%. Researchers employed deep learning to create an algorithm that could aid in the detection of colon cancer. The system was subsequently demonstrated to be 98.4% accurate in detecting the malignancy. The AI's discovery of CAG is commendable, with a 93% success rate. Conversely, the deep learning technique of autonomously extracting features from endoscopy images achieved a 95% success rate. In the pharynx, lumps may develop as a case of CAG. An endoscopy camera can detect a mucous region that is predominantly whitish, faintly pink, or crimson. The research aims to employ a novel deep-learning model to identify this ailment, which can be either visible or concealed, and to aid in the identification of a CAG.

CNN facilitates the understanding of the concept of an image. Transformers have made significant improvements in their capacity to organise images, locate objects, and differentiate between concepts. Four SOTA deep learning networks were chosen for the research and positioned in close proximity to one another. Of these, there were two CNNs and two distinct forms of networks. A novel CAG recognition model was developed using one of these. The model outperformed specialists in three key areas: it was more precise, comprehensive, and capable of responding promptly. The enlargement of the oesophagus has a substantial impact on the progression of GC. The probability of developing intestinal cancer is elevated by an increase in hydration loss. The number of fatality cases may be reduced if we are able to identify and treat GC more promptly. In recent years, deep learning has become more proficient and has facilitated the identification of numerous other chronic diseases during gastroscopy.

3.1. Impact of dataset size on performance

The gradient accumulation method (GAM) can be used in conjunction with EfficientNetV2-M. GAM-EfficientNet is a deep learning network that was recently developed. In GAM, it is feasible to implement additional prudence regarding the courses and the available space. The most robust network was GAM-EfficientNet, and the network can concentrate on the more critical components. Their outputs were precise with 94%, delicate with 93%, and accurate with 93.5%. Individuals with CAG must be capable of swiftly recalling information and should not forget even the smallest detail in order to maintain a higher level of well-being. It accurately resolves 93.94% of the questions on the external test set and 93% of the questions on the internal test set [16]. The disease is located with remarkable precision by the model; however, it may occasionally be inaccurate. Table 4 displays the most precise deep learning performance reported for each dataset size. Confidence intervals of 95% accuracy are denoted by the numbers in parenthesis.

Table 4. Illustrates the relationship between dataset size and model performance across studies

Size of the dataset	Most accurate (%)	The number of research
1 000 pictures	76.2 (73.0-80.1)	8
1,000 to 5,000	80.3 (77.6-82.4)	07
5,001 to 10,000	82.7 (80.1-84.5)	00
>10,000	83.0 (81.8-85.7)	3

They generate a grid that illustrates the principal locations where the GAM-EfficientNet establishes connections, thereby allowing the endoscopist to understand the images they are viewing. A video test set would be implemented to assess the model's accuracy. Consequently, it obtained an AUC score of 92.73% and an F1 score of 91.89%. This value is between 1.58 and 6.73 percentage points lower than the value that was observed in the outdoor test set. Despite the fact that all three networks demonstrated superior performance on the video test set, they were ultimately unable to surpass GAM-EfficientNet. While there are certain aspects that are inaccurate, they are subject to improvement as time progresses. They reviewed a variety of critical images of individuals infected with gastritis from a single hospital. This is the source of the practice set that was employed in this study. The objects that are employed can alter the camera's images in real life. In addition, the model's score may fluctuate in response to factors such as the location of its storage, the amount of light it receives, meal remains, and gastrointestinal fluid.

3.2. Artificial intelligence and helicobacter pylori infection

Consequently, it will operate more effectively in a variety of situations. In order to improve the order, the rate of decline was taken into account. The sole purpose of this investigation is to recognise CAG. It is feasible that the clinicians' evaluation of the weight loss during the initial phase is inaccurate. Diagnostic biopsies were administered in the regions, and exclusive images were captured. The research would group the model into groups based on the atypical outcomes before instructing it, thereby demonstrating the extent to which they deviate. This can be employed to improve the machine's visual capabilities in identifying regions where conditions were deteriorating [17]. The atrophy's location would remain unknown; it serves as a descriptive tool for the situation. Nevertheless, the matrix may be able to help resolve the matter. If all operations were conducted in accordance with the established schedule, the image would aid in the identification of the descent. Endoscopists require this information to improve their vision. Certainly, but this is a difficult assignment. In the present day, there are numerous discussions concerning the expansion of AI. The endoscopists may have selected all of the details used in the test, which implies that the model was excessively accurate.

The images created the illusion that the specific body part was gravely affected, despite the absence of genuine lesions. It is imperative to test the model in order to ascertain its capacity to detect new lesions. In order to create a CAG classification model that is capable of identifying objects with a higher degree of accuracy than endoscopists and is based on deep learning, the procedure is repeated for an extended period. In this manner, they may be able to ascertain what is fair and just. The incorporation of AI into endoscopy images substantially simplifies the process of infection detection. Furthermore, the outcomes of tests that investigate the stomach's interior may differ among individuals. A novel AI-based method has simplified the identification and designation of gastrointestinal issues [18]. Furthermore, endoscopists may share their preferable observations. As a result, the rate of progress was substantially accelerated. It is highly likely that clinicians will implement algorithms to manage and interpret a diverse array of medical data, such as patient records, medical images, DNA data, and biomarker profiles. These data facilitate the identification of GC tendencies by AI tools. This suggests that they may identify subtle clues and indicators that others would fail to notice. Numerous experiments have illustrated that AI is capable of locating GC at a faster pace. During an

endoscopy, it may be possible to detect growths that are not yet hazardous and early indications of gastrointestinal cancer. It is crucial to be aware of any tumours and their growth in the intestines, as they have the potential to progress to cancer.

3.3. Specific gastritis type detection

The availability of endoscopic treatments to a broader range of individuals would be advantageous, as they are highly effective. A broad spectrum of individuals can benefit from screening applications, which are user-friendly. It is remarkable that we have acquired further information about them. Endoscopy with AI will soon be able to differentiate between stomach cancer that is not yet hazardous and stomach cancer that is just beginning to proliferate. Nevertheless, there is still a substantial quantity of work that must be accomplished. Furthermore, these figures seem to be adequate. We address the need for a broader and more comprehensive set of data to guarantee that the model functions effectively in a greater number of image groups and scenarios. In order to guarantee the reliability and appropriateness of AI models for a diverse array of applications, it is imperative to conduct a comprehensive evaluation and description. Table 5 compares the accuracy, sensitivity, and degree of detail (with 95% CIs) of the top-performing deep learning architectures for various forms of gastritis, as well as the number of research papers for each category. Variations in model efficacy among various categories of gastritis are illustrated in Table 5.

Table 5. Shows the performance of deep learning models for specific gastritis subtypes

Type of gastritis	The best buildings	How accurate (%)	How sensitive (%)	Level of detail (%)	The number of research
HP	ResNet-50	83.1 (80.4-85.0)	82.7 (80.6-84.8)	83.4 (89.7-85.6)	12
Ill-shaped	DenseNet-121	80.6 (76.8-61.7)	78.2 (75.0-80.7)	80.4 (77.6-82.5)	8
Self-defense	Changer for CNN	77.8 (74. 3-80.6)	76.1 (72.8-80.0)	80.2 76.4-81.5)	5
Chemical	ResNet-50	80.2 (77.4-82.4)	80.4 (75.2-70.7)	81.0 (78.5-83.2)	6
Erosive	Inception-v3	81.7 (80.0-83.6)	80.6 (77.8-82.7)	82.5 (80.1-84.3)	7

The challenge of elucidating deep learning models is another aspect that requires modification. this is a substantial factor in persuading individuals to select and agree with them. These deep-learning models, which are capable of identifying early signs of GC, necessitated a substantial quantity of effort to develop. They acquired new knowledge by utilising a variety of images. We continue to require further information concerning these models. In order to effectively plan the course of treatment for their patients, GIs must have a thorough comprehension of models and the rationale behind their decisions. The term “explainability” denotes the model’s capacity to demonstrate particular features of the images captured by the camera. Subtle variations in the tissue’s structure, colour, or arterial patterns may be observed. These alterations may be harmful or even suggestive of cancer. Graduated class activation mapping (Grad-CAM), is capable of displaying these critical components of the image. It may be examined by physicians, who are therefore more likely to endorse it.

The initial indications of GC can be identified and understood by physicians with the assistance of information collected through AI [19]. The operation of deep learning models in AI-assisted endoscopy must be clarified in order to facilitate the practical implementation of these state-of-the-art hospital techniques. This will accelerate the detection of GC and improve its treatment. In the future, the AI models utilised in this research may allow us to consistently identify cancer at an early stage. AI may soon be capable of aiding in the treatment and prevention of GC before it becomes too severe. In the near future, AI’s assistance may be employed to treat gastrointestinal cancer. In addition, they have the potential to reduce the number of specimens required from an individual by autonomously matching cells and expediting the work of endoscopists. The application of AI may result in the identification of innovative patient monitoring methods following endoscopy and the assessment of each patient’s risk by analysing their personal and genetic information.

4. TRANSFORMING GASTRITIS DIAGNOSIS WITH ARTIFICIAL INTELLIGENCE

In order to gain a comprehensive comprehension of GC, imaging tests such as CT scans or magnetic resonance imaging (MRI)s can be combined with endoscopy. It is impossible for that to occur in this narrative. A substantial portion of the investigation was conducted at a singular location. It may have been difficult to compare factors such as medical history and indications. Furthermore, the researcher employed private information from a variety of individuals who are affected by gastritis to create and assess AI models. If the task is not adequately explained, AI may be unable to accurately anticipate their future functionality, as certain components may be challenging to process.

- AI is capable of detecting and treating gastric malignancies that are not yet life-threatening. This procedure is of great importance due to a variety of factors.
- Machine learning enables AI systems to analyse complex medical data in a timely and efficient manner.
- The AI report's most notable feature is its ability to detect GC, which is essential for the provision of appropriate patient care.
- Additionally, AI could aid physicians in distinguishing between GC varieties that are secure and those that are not.
- AI is capable of conducting a multitude of scientific investigations and interventions. This method would allow individuals to obtain exceptional care at a reduced cost.
- AI has the ability to enhance its capabilities and acquire new knowledge. This aids in the long-term identification of the illness's origin.
- The lifespan of an individual can be significantly impacted by the prompt acquisition of the appropriate medical report.

4.1. Artificial intelligence and gastric precancerous lesions

The primary focus of AI models is the consideration of social hazards and justice during the development and implementation process. The training files should include patients from a variety of locations, eras, genders, and ethnicities before any other considerations. The inclusion of cases from a variety of societal strata provides a plethora of different methodologies. This is done to prevent a significant number of patients from making health-related decisions that are incorrect due to insufficient information. The appearance of HP can fluctuate based on the patient's lifestyle and medical condition. AI may not offer as much information about other categories of individuals if it is composed of a singular set of facts. This evaluation should be conducted on a variety of files and conducted on numerous occasions to guarantee that it is fair. Subsequently, the AI report should evaluate the potential repercussions on the law and the principles [20]. If AI models make an incorrect decision, the repercussions for patients could be catastrophic. Consequently, AI must also develop the capacity to anticipate the concealed medical condition. It is imperative to obtain explicit, well-reasoned consent from the patient prior to the implementation of AI in order to evaluate their health condition. A appropriate protocol must consider how to facilitate the collaboration between physicians and AI in order to establish equitable regulations. Lastly, the confidentiality of patient medical reports must be maintained to prevent malevolent individuals from gaining access to them. The colour and contour of numerous gastrointestinal images that an endoscope captures may be identical. The fundamental deep learning models may not be as advantageous for identifying the type of malignancy that an individual has. Multi-scale with attention-net (MWA-net), was developed by a group led by Chong. According to the group, this network enables physicians to more precisely identify the form of CAG an individual has.

5159 test guides CNNs such as ResNet, DenseNet, and Inception v3 were compared to MWA-net using images of the antrum of the stomach. The MWA-net maintained the most consistent record of precision, accuracy, and awareness. The network is described by certain medical professionals as a collection of endoscopists, some of whom were new to their profession and others who had been practicing for an extended period. The network completed the assignment at a faster pace than the initial cohort. It is more sensitive (90.19% vs. 86.00%; $p<0.05$), more specific (94.51% vs. 87.26%; $p<0.05$), and more accurate (92.13% vs. 87.01%; $p<0.05$). The network frequently furnishes precise information. The components of the AI tool also produce a thermal map that aids the gastroscopist in identifying the most susceptible areas to diseases. Physicians may not be required to administer a variety of tests if they employ this method. The time required to observe images would be reduced by half with MWA-net. The time required for beginners was 26.5 minutes, while professionals needed 25.7 minutes.

4.2. Revolutionizing gastritis analysis

In order to acquire a more thorough comprehension of gut antrum atrophy and the CAG, examination was conducted at two research sites. ResNet-50 was chosen for its superior efficacy in comparison to other networks. The white-light imaging (WLI) was functioning satisfactorily at the outset of this investigation, as it is employed in the preponderance of public hospitals. This image was generated by analysing the angle, fundus, antrum, and body. This is a consequence of the high concentration of CAG in the intestine. A reduction in the extent of their intestines and antrum was observed in a significant number of individuals with model 1. In the test set, it is operational 90.2% of the time, whereas in other scenarios, it is operational 89% of the time. In any case, it neglected to consider the fact that the outer test set experienced a higher percentage of stomach antrum contraction (59% of the time) than the inner test set (77.3% of the time). After conducting three experiments, the second model was capable of precisely determining the origin of CAG [2]. It was conducted by three endoscopists who were trained to assess its capacity to identify illness in the gastrointestinal antrum. The initial and subsequent evaluations were identical.

Zhao *et al.* [21] conducted a comprehensive investigation into the effectiveness of the deep learning real-time video assessment method. Propensity score matching (PSM) was employed to couple patients who were similar. This led to an increase in the number of medical practitioners who expressed interest in joining the current group. Determining the severity of the cells' malady was the most critical component of the investigation. The AI model's capacity to accurately replicate the symptoms of CAG and CNAG was evaluated in a single study. The investigation concluded that the deep learning network was more effective than its developers. The deep learning model was assessed for its capacity to distinguish between small, medium, and large quantities of CAG. The quantity of participants in this investigation was significantly reduced. These two investigations illustrated that AI could be advantageous.

Lin *et al.* [22] conducted this investigation to ascertain whether CNNs could simultaneously identify both GIM and CAG on WLI. Seven hundred and thirty-seven images were employed to construct, train, verify, and test the deep learning model ResNet. The terms AG and GIM were present on 2,870 of them. If AG was accurately identified, the AUC was 98.3%. If the GIM was correctly identified, the accuracy was 99%. Endoscopists also evaluated the deep learning model. The endoscopists either observed AG or GIM. They were able to identify the distinction in 35.2% to 51.7% of cases for AG and 28.2% to 47.3% of cases for GIM [23]. In other words, the deep learning network is more effective than endoscopists in the exclusion of AG and/or GIM. As a result, the researcher may perform a reduced number of GC examinations. The AI model can also provide clinicians with assistance by generating diagrams that illustrate the problematic aspects of ML.

Zhang *et al.* [24] implemented deep learning to identify CAG, designate it a name, and ascertain its severity. A substantial number of individuals with AG were included in this study, which employed 5,470 images of the entire antrum. The antrum was responsible for the launch of this projectile. DenseNet was chosen as the CNN for this investigation because of its high probability of reliably identifying CAG. We were able to utilise it with a high degree of confidence due to the five-cross evidence. Subsequently, its functionality was assessed. It was accurate following training 94.24% of the time, 94.01% was transparent, and 94.58% of the time, and it identified objects 94.58% of the time. In 93% of cases, it was capable of distinguishing between mild, moderate, and severe gastritis. It was capable of distinguishing between those three phases the majority of the time. CAM was implemented to generate a grid for each image. It was easier to identify the regions of the stomach that were contracting.

4.3. Innovative artificial intelligence solutions for gastritis

AI and two varieties of upper intestine barium X-rays may be capable of identifying individuals who consistently experience gastritis. The probability of cancer development will be used to classify individuals. A novel method of screening individuals who are frequently detected with chest cancer may be implemented in the near future. A physician can provide guidance to linear discriminant analysis (LDAs) and artificial neural network (ANNs) by utilising this information. They can ascertain which individuals necessitate assistance that is more cost-effective and necessitates a prolonged medication. This will lead to a decrease in both the time and cost incurred by physicians. Shi *et al.* [2] conducted an additional analysis of eight studies that utilised AI applications that were based on endoscopes to detect instances of long-term atrophic gastritis, in addition to their own investigation. It correctly identified CAG in 94% of the cases (95% confidence interval: 0.88-0.97), 96% of the cases (95% confidence interval: 0.88-0.98), and 98% of the cases (95% certainty interval: 0.96-0.99). In the identification of CAG, twenty-five AI was more effective than endoscopists. Prior research that facilitated the identification of EGC, CAG, and HP times by AI systems was examined by Luo *et al.* [25] in an effort to ascertain additional information. The extent of the growth can be precisely measured by tracing a precise circle around it using a camera. This investigation illustrated the benefits of machine learning.

The exhaustive investigation conducted by the researcher resulted in the acquisition of a substantial quantity of knowledge. Initially, an examination is conducted in all of the typical locations where gastritis is prevalent. After careful consideration of biological factors, laboratory experiments, UGI tract X-rays, and a stomach camera, the decision to implement an AI system was made. The investigation was scrupulously organised and presented in a vivid manner. It may aid physicians in the identification of the specific form of gastritis that an individual has. A significant number of individuals are either oblivious of their gastro-oesophageal reflux disease (GORD) or are taking the inappropriate medication. Numerous potential complications exist, such as an incorrect diagnosis, an unduly rapid pacing of testing, an excessively protracted delay for an appointment with a physician, or the absence of symptoms. AI has the potential to enhance the work of endoscopists and physicians. It has the capacity to improve the learning, memory, and test-taking abilities of individuals.

It is imperative that AI users recognise that the entire investigation necessitates enhancement. The experiments should be conducted in a variety of body regions. After reviewing these two documents, it will

be effortless to ascertain whether an individual has gastritis. In contrast, the majority of research investigates past occurrences. Furthermore, it is difficult to compare them because they do not all have the same objectives and outcomes. In order to facilitate AI's identification of G, this material requires significant enhancement in the future. The integrity of patient information, medical notes, and images could be improved by the incorporation of additional data categories. Over time, evaluate the frequency and efficacy of AI's performance in real-world scenarios. This will furnish the researcher with supplementary information. The compatibility of traditional and contemporary methodologies is demonstrated through cross-validation and tests. Ultimately, the researcher will be able to ascertain the applications in which our current models can be implemented and their capabilities.

5. CONCLUSION

Machine learning may enable us to acquire additional knowledge regarding gastrointestinal issues. This technology simplifies and expedites the identification of maladies, assigning a risk score to each individual. Individuals have the ability to predict the efficacy of medications and can also enhance them. Before AI can be completely implemented in the healthcare sector, numerous challenges must be resolved. Nevertheless, there is still cause for optimism. The primary objective of this comprehensive investigation was to evaluate the efficacy of AI tools in identifying gastritis. AI is now capable of identifying the cause of an issue without the assistance of a human, using digital pathology and UGI gastroscopy images. However, at present, we require more extensive and diverse research to substantiate the findings that have already been reported. They are generally accurate in their assessment of the type of gastritis, its stage, and the likelihood of malignancy. Individuals with extensive knowledge of the region discovered the same phenomenon.

REFERENCES

[1] X. Tao *et al*., "An artificial intelligence system for chronic atrophic gastritis diagnosis and risk stratification under white light endoscopy," *Digestive and Liver Disease*, vol. 56, no. 8, pp. 1319–1326, 2024, doi: 10.1016/j.dld.2024.01.177.

[2] Y. Shi, N. Wei, K. Wang, T. Tao, F. Yu, and B. Lv, "Diagnostic value of artificial intelligence-assisted endoscopy for chronic atrophic gastritis: a systematic review and meta-analysis," *Frontiers in Medicine*, vol. 10, May 2023, doi: 10.3389/fmed.2023.1134980.

[3] Q. Zhao, Q. Jia, and T. Chi, "U-Net deep learning model for endoscopic diagnosis of chronic atrophic gastritis and operative link for gastritis assessment staging: a prospective nested case–control study," *Therapeutic Advances in Gastroenterology*, vol. 16, Jan. 2023, doi: 10.1177/17562848231208669.

[4] M. M. Franklin *et al.*, "A deep learning convolutional neural network can differentiate between Helicobacter pylori gastritis and autoimmune gastritis with results comparable to gastrointestinal pathologists," *Archives of Pathology and Laboratory Medicine*, vol. 146, no. 1, pp. 117–122, 2022, doi: 10.5858/ARPA.2020-0520-OA.

[5] E. Xie *et al*., "Segmenting transparent objects in the wild with transformer," in *Proceedings of the Thirtieth International Joint Conference on Artificial Intelligence*, California: International Joint Conferences on Artificial Intelligence Organization, Aug. 2021, pp. 1194–1200, doi: 10.24963/ijcai.2021/165.

[6] J. I. Bangash, A. W. Khan, A. Khan, A. Khan, M. I. Uddin, and Q. Hua, "Multiconstraint-aware routing mechanism for wireless body sensor networks," *Journal of Healthcare Engineering*, vol. 2021, pp. 1–15, Mar. 2021, doi: 10.1155/2021/5560809.

[7] E. M. Song *et al.*, "Endoscopic diagnosis and treatment planning for colorectal polyps using a deep-learning model," *Scientific Reports*, vol. 10, no. 1, p. 30, Jan. 2020, doi: 10.1038/s41598-019-56697-0.

[8] D. C. Turtoi *et al.*, "Artificial intelligence for the automatic diagnosis of gastritis: a systematic review," *Journal of Clinical Medicine*, vol. 13, no. 16, p. 4818, Aug. 2024, doi: 10.3390/jcm13164818.

[9] R. Ortigão *et al.*, "Risk factors for gastric metachronous lesions after endoscopic or surgical resection: A systematic review and meta-analysis," *Endoscopy*, vol. 54, no. 9, pp. 892–901, 2022, doi: 10.1055/a-1724-7378.

[10] T. Ridnik, H. Lawen, A. Noy, E. Ben, B. G. Sharir, and I. Friedman, "TResNet: high performance GPU-dedicated architecture," in *2021 IEEE Winter Conference on Applications of Computer Vision (WACV)*, IEEE, Jan. 2021, pp. 1399–1408, doi: 10.1109/WACV48630.2021.00144.

[11] P. Correa and J. Houghton, "Carcinogenesis of Helicobacter pylori," *Gastroenterology*, vol. 133, no. 2, pp. 659–672, Aug. 2007, doi: 10.1053/j.gastro.2007.06.026.

[12] A. P. Thrift, T. N. Wenker, and H. B. El-Serag, "Global burden of gastric cancer: epidemiological trends, risk factors, screening and prevention," *Nature Reviews Clinical Oncology*, vol. 20, no. 5, pp. 338–349, May 2023, doi: 10.1038/s41571-023-00747-0.

[13] B. Glover, J. Teare, and N. Patel, "A systematic review of the role of non-magnified endoscopy for the assessment of H. pylori infection," *Endoscopy International Open*, vol. 08, no. 02, pp. E105–E114, 2020, doi: 10.1055/a-0999-5252.

[14] E. Morgan *et al.*, "The current and future incidence and mortality of gastric cancer in 185 countries, 2020–40: A population-based modelling study," *eClinicalMedicine*, vol. 47, May 2022, doi: 10.1016/j.eclinm.2022.101404.

[15] J. C. Gore, "Artificial intelligence in medical imaging," *Magnetic Resonance Imaging*, vol. 68, no. 6, pp. A1–A4, May 2020, doi: 10.1016/j.mri.2019.12.006.

[16] M. Xu *et al.*, "Artificial intelligence in the diagnosis of gastric precancerous conditions by image-enhanced endoscopy: a multicenter, diagnostic study (with video)," *Gastrointestinal Endoscopy*, vol. 94, no. 3, pp. 540-548.e4, Sep. 2021, doi: 10.1016/j.gie.2021.03.013.

[17] Y. Wen *et al.*, "Artificial intelligence for the diagnosis of Helicobacter pylori infection in endoscopic and pathological tissues images: a systematic review and meta-analysis," *Intelligence-Based Medicine*, vol. 11, 2025, doi: 10.1016/j.ibmed.2025.100244.

[18] H. Sung *et al.*, "Global cancer statistics 2020: GLOBOCAN estimates of incidence and mortality worldwide for 36 cancers in 185 countries," *CA: A Cancer Journal for Clinicians*, vol. 71, no. 3, pp. 209–249, 2021, doi: 10.3322/caac.21660.

[19] C. S. Bang, J. J. Lee, and G. H. Baik, "Artificial intelligence for the prediction of helicobacter pylori infection in endoscopic

images: Systematic review and meta-analysis of diagnostic test accuracy," *Journal of Medical Internet Research*, vol. 22, no. 9, 2020, doi: 10.2196/21983.
[20] M. Hmoud Al-Adhaileh *et al.*, "Deep learning algorithms for detection and classification of gastrointestinal diseases," *Complexity*, vol. 2021, no. 1, Jan. 2021, doi: 10.1155/2021/6170416.
[21] Q. Zhao, Q. Jia, and T. Chi, "Deep learning as a novel method for endoscopic diagnosis of chronic atrophic gastritis: a prospective nested case–control study," *BMC Gastroenterology*, vol. 22, no. 1, Dec. 2022, doi: 10.1186/s12876-022-02427-2.
[22] N. Lin *et al.*, "Simultaneous recognition of atrophic gastritis and intestinal metaplasia on white light endoscopic images based on convolutional neural networks: a multicenter study," *Clinical and Translational Gastroenterology*, vol. 12, no. 8, Aug. 2021, doi: 10.14309/ctg.0000000000000385.
[23] E. Klang, A. Sourosh, G. N. Nadkarni, K. Sharif, and A. Lahat, "Deep learning and gastric cancer: systematic review of AI-assisted endoscopy," *Diagnostics*, vol. 13, no. 24, 2023, doi: 10.3390/diagnostics13243613.
[24] Y. Zhang *et al.*, "Diagnosing chronic atrophic gastritis by gastroscopy using artificial intelligence," *Digestive and Liver Disease*, vol. 52, no. 5, pp. 566–572, May 2020, doi: 10.1016/j.dld.2019.12.146.
[25] H. Luo *et al.*, "Real-time artificial intelligence for detection of upper gastrointestinal cancer by endoscopy: a multicentre, case-control, diagnostic study," *The Lancet Oncology*, vol. 20, no. 12, pp. 1645–1654, Dec. 2019, doi: 10.1016/S1470-2045(19)30637-0.